

Histopathological Assessment of Patient-Derived Xenografts		
Laboratory:	Molecular Characterization and Clinical Assay Development Laboratory	
Effective Date:	8/12/2014	Page 1 of 3

## 1.0 PURPOSE/SCOPE

This Standing Operating Procedure (SOP) describes the histopathological criteria that are reported following examination of H&E stained sections of Patient-Derived Xenografts (PDX) by a board-certified pathologist. This SOP is used/performed by the Molecular Characterization and Clinical Assay Development Laboratory (MoCha) at the Frederick National Laboratory for Cancer Research.

## 2.0 RELATED DOCUMENTS

Source	Title
Publication	American Joint Committee on Cancer. <i>AJCC Cancer Staging Manual</i> . 7th ed. New York, NY: Springer; 2010

## 3.0 DATABASE FIELDS FOR HISTOPATHOLOGICAL ASSESSMENT

### 3.1 Tumor Grading in PDX models

**3.1.1** 1 (Low grade or well differentiated)

**3.1.2** 2 (Intermediate grade or moderately differentiated)

**3.1.3** 3 (High grade or poorly differentiated)

### 3.2 Percent Tumor, Stromal, and Necrotic Cell Content (0%-100%)

### 3.3 Inflammatory Cell Infiltrate Scoring

**3.3.1** 1+ (Low)

**3.3.2** 2+ (Moderate)

**3.3.3** 3+ (High)

### 3.4 Pathology Notes

**3.5** After 2-3 PDX generations have been assessed, an assignment of Yes/No for “Diagnosis Confirmed in PDX” is associated with the PDX patient’s record.

## 4.0 CRITERIA DEFINITIONS

### 4.1 Tumor Grading in PDX models

**4.1.1** Tumor grade is the description of a tumor based on how abnormal the malignant cells and tumor tissue histology appear; it is an indicator of how quickly a tumor is likely to grow and spread. If the cells of the tumor and the organization of the tissue are close to those of normal cells and tissue, the tumor is called “Well differentiated.” These tumors tend to grow and spread at a slower rate than tumors that are “Poorly differentiated,” which have abnormal-looking cells and may lack normal tissue structures.

Based on these and other differences in microscopic appearance, Tumor Grade is assigned in humans; we have utilized the similar approach to grade the PDXs.

Histopathological Assessment of Patient-Derived Xenografts		
Laboratory:	Molecular Characterization and Clinical Assay Development Laboratory	
Effective Date:	8/12/2014	Page 2 of 3

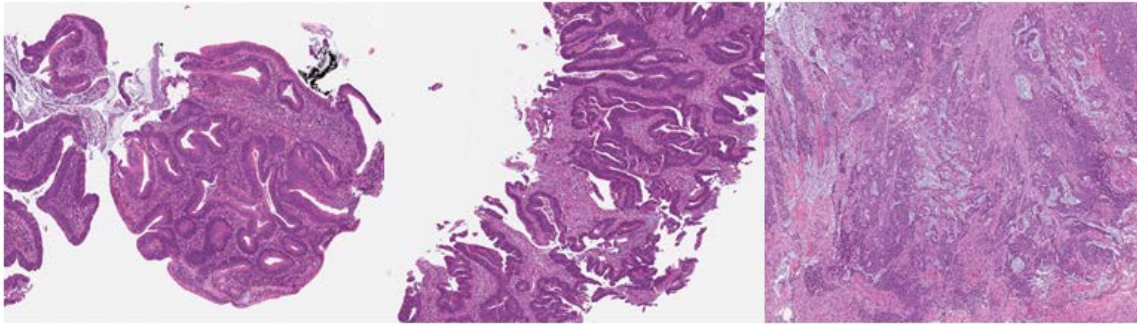
- 4.1.2** Grading systems differ depending on the type of cancer. For the PDX tumors, we have generally assigned Tumor grades as follows (sample images in Appendix 1, Section 1):
- **Well differentiated (Low grade):** These tumors and the organization of the tumor tissue appear close to normal; these tumors tend to grow and spread slowly.
  - **Moderately differentiated (Intermediate grade):** These tumors cells are less differentiated than Low grade tumors, but maintain the architecture of the primary tumor.
  - **Poorly differentiated or Undifferentiated (High grade):** These tumor cells do not look like normal cells or tumor tissue; these tumors tend to grow rapidly and spread faster than tumors with a lower grade.
- 4.2** Percent Tumor, Stromal, and Necrotic Cell Content (sample images in Appendix 1, Section 2):
- 4.2.1** The percentage of tumor, stromal, and necrotic cells relative to other cells present in a tissue section are estimated and scored in categories of 0%-5%, 6%-10%, 11%-20%, 21%-30%, 31%-40%, 41%-50%, 51%-60%, 61%-70%, 71%-80%, 81%-90%, and 91%-100%.
- 4.2.2** Stromal content includes areas of normal cells infiltrating the PDX tumors including fibroblasts, histiocytes and inflammatory cells; the inflammatory component is primarily host-derived. Early-passage PDX stromal components may include stroma of human tumor origin, while later passages tend to be host-derived.
- 4.3** Inflammatory Cell Infiltrate Scoring
- 4.3.1** Scoring of the inflammatory reaction is based on the general impression of the amount of inflammatory cells associated with the entire H&E tumor section. When possible, an attempt is made to establish what inflammatory cells are present in the tumor section (e.g., mononuclear cells including lymphoid and plasma cells, eosinophils, and neutrophils).
- **1+ (Low):** Occasional-to-rare inflammatory cells are associated with the tumor section (e.g., 1-10 inflammatory cells per 10 tumor cells)
  - **2+ (Moderate):** Many inflammatory cells are present with a range of 10-100 inflammatory cells per 10 tumor cells
  - **3+ (High):** Clusters of inflammatory cells are present and can include abscesses, histiocytic expansion, or lymphoid aggregates within the tumor or along the tumor margin.
- 4.4** Pathology Notes
- 4.4.1** In addition, to summarizing the type of inflammatory cells present in the tumor section, the board-certified pathologist will include additional notes on cell shapes, interpretation of diagnosis sub-type based on histology, mitotic assessment, and tissue and nuclear architecture.

Histopathological Assessment of Patient-Derived Xenografts		
Laboratory:	Molecular Characterization and Clinical Assay Development Laboratory	
Effective Date:	8/12/2014	Page 3 of 3

**APPENDIX 1: HISTOPATHOLOGY IMAGES**

**1. Determination of Tumor Differentiation**

**Colon Adenocarcinoma**



Well Differentiated

Moderately Differentiated

Poorly Differentiated

**2. Percent Tumor, Necrotic, and Stromal Cell Content**

$$\text{Tumor Content (\%)} = \frac{\text{Tumor Area}}{\text{Viable Tumor} + \text{Necrotic Tumor} + \text{Stromal Area}}$$

